

## SCREENING OF METHANOLIC EXTRACT OF FOENICULUM VULGARE FOR HEPATOPROTECTIVE ACTIVITY

V. DEVIKA\*<sup>1</sup>, DR. S. MOHANDASS<sup>2</sup>, AISWARY A. P. R<sup>3</sup>

<sup>1,3</sup>Department of Biochemistry, Dr. N. G. P. Arts and Science College, Coimbatore 48, <sup>2</sup>Kaamadhenu Arts and Science College, Sathyamangalam 638503. Email:devikangp@gmail.com

Received: 03 Apr 2013, Revised and Accepted: 12 Sep 2013

### ABSTRACT

**Objective:** The present study was carried out in various parts of the plant '*Foeniculum vulgare*' (Shoots, Stems & Leaves) to evaluate the hepatoprotective potency against paracetamol induced toxicity which includes biochemical assessment of liver marker enzymes in serum and biochemical assessment of hepatic marker enzymes.

**Methods:** The methanolic extracts of *Foeniculum vulgare* (200mg/kg and 400mg/kg) were administered orally to the animals and hepatotoxicity induced by paracetamol (2mg/kg). The extracts were administered orally by suspending in 1 %w/v carboxy methyl cellulose solution. Silymarin (0.1mg/kg dose) was given as standard reference.

**Results:** The methanolic extract showed a significant decrease in serum markers SGOT, SGPT, ALP and Bilirubin was estimated and found to be increased during paracetamol toxicity (400mg/kg dose). The hepatic marker enzymes such as AST and ALT was estimated and found to be decreased in paracetamol induced hepatotoxicity. It showed no significant activity at 200mg/kg dose.

**Conclusion:** It was concluded from the result that methanolic extract of *Foeniculum vulgare* possess hepatoprotective activity against paracetamol induced hepatotoxicity in wistar albino rats.

**Keywords:** *Foeniculum vulgare*, Carboxy methyl cellulose, Silymarin, Paracetamol.

### INTRODUCTION

The liver is necessary for survival; there is currently no way to compensate for the absence of liver function long term, although liver dialysis can be used short term [1]. Many drugs undergo chemical change in the liver before excretion in bile. They may damage the liver cells in their original form or in various intermediate stages. The liver's highly specialized tissues regulate a wide variety of high-volume biochemical reactions, including the synthesis and breakdown of small and complex molecules, many of which are necessary for normal vital functions [2]. The large number of chemical agents administered for therapeutic or diagnostic purpose can produce various types of hepatic injury by several mechanisms [3]. Paracetamol toxicity is the foremost cause of acute liver failure in the Western world, and accounts for most drug overdoses in the United States, the United Kingdom, Australia and New Zealand [4]. Fennel *Foeniculum vulgare* belonging to the Family *Umbelliferae* is an annual, biennial or perennial aromatic herb, depending on the variety, the leaves, stalks and seeds (fruits) of the plant are edible. *Foeniculum vulgare* is an aromatic herb whose fruits are oblong, ellipsoid or cylindrical, straight or slightly curved and greenish or yellowish brown in colour [5]. Since no previous attempts have been made to evaluate the hepatoprotective activity of *Foeniculum vulgare* extract on experimental animals.

### MATERIALS AND METHODS

#### Animals used

Male albino rats of wistar strain weighing between 100-150 gm were obtained from Small Animal Breeding Center, Kerala Agricultural University, Trissur. The animals were housed in larger spacious cages and they were given food and water *ad libitum* during the course of the experiment. The animal room was well ventilated and the animal had a 10 ± 1 hour night schedule, throughout the experiment period. The atmospheric temperature remained between 30°C to 37°C with only 5°C differences. Clearances for the handling of experimental animals were obtained from the Ethical Committee CPCSEA No. KMCRET/PhD/7/2009.

#### Diet used

The commercial pelleted animal feed marketed by M/s Hindustan Lever Limited, Bangalore, India, under the trade name of "Gold Mohur rat feed" was used.

#### Chemicals used

##### Sources of fine chemicals

All chemicals and solvents used were analytical grade, and purchased from SD Fine Chemicals, Himedia and Qualigens, India.

##### Experimental Design

Rats were divided into five groups of six animals each. Liver damage was induced by administration of Paracetamol (2mg/kg/bw), a day prior to the treatment.

**Group I** - Normal rats served as control

**Group II** - Rats were administered Paracetamol (2 mg/kg/ bw, orally) for 14 days.

**Group III** - Rats were administered both Paracetamol + Silymarin (0.1mg/kg/bw, orally)

**Group IV** - Rats were administered both Paracetamol + Methanolic extract of *Foeniculum vulgare* (200mg), (orally).

**Group V** - Rats were administered both Paracetamol + Methanolic extract of *Foeniculum vulgare* (400mg), (orally).

At the end of the experimental period, the animals were sacrificed by cervical decapitation and blood was collected. Liver were removed and washed with ice-cold saline and their weights recorded.

##### Preparation of Tissue Homogenate

A 10% homogenate of the washed liver tissues were prepared in 0.01M Tris-HCl buffer, pH 7.4. The homogenate was centrifuged at 2500g for 30min and the supernatant was used for the assay of enzymes.

##### Statistical Analysis

The values obtained from each group were expressed as Mean ± Standard deviation. One way Anova was done to compare the statistical significant changes between control, Paracetamol induced hepatotoxicity, Silymarin treatment rats and with *Foeniculum Vulgare* extracts treatment. The p-value was computed to detect the significant (p<0.05) changes within the group. The significant levels between the groups was compared using DMRT.

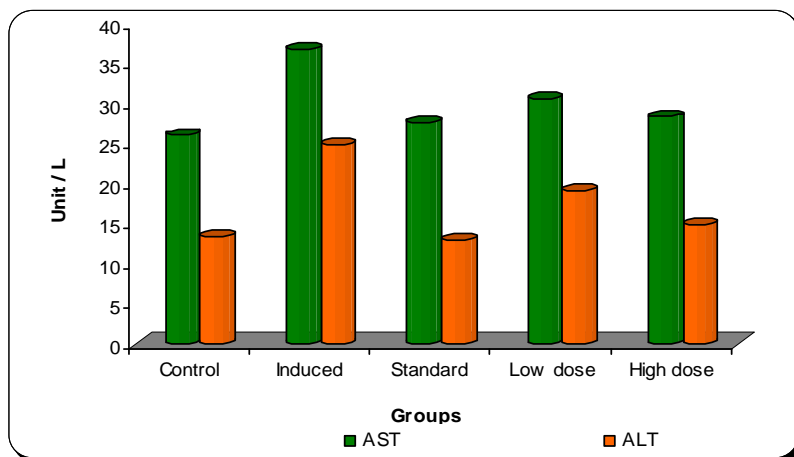


Fig. 1: activity of ast and alt in serum of control and experimental animals

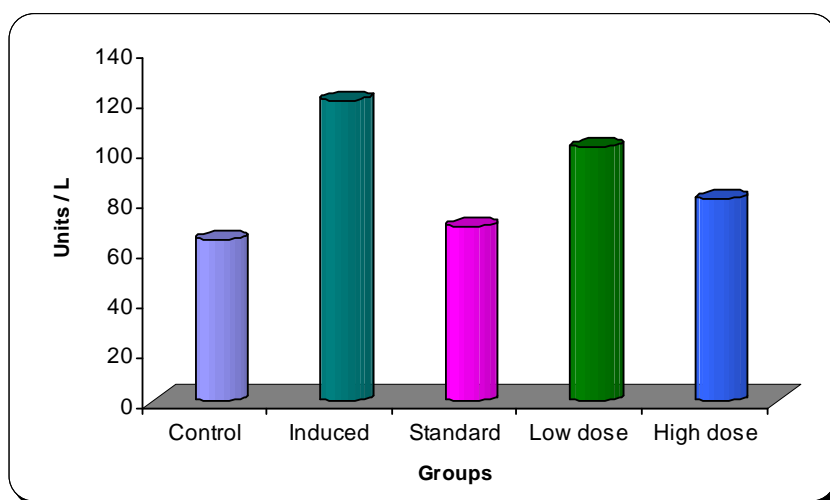


Fig. 2: activity of alp in serum of control and experimental animals

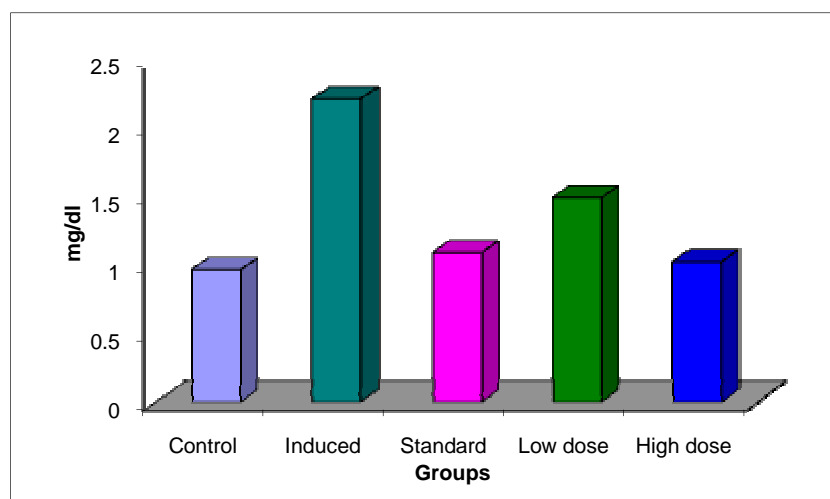


Fig. 3: activity of bilirubin in serum of control and experimental animals

**RESULTS AND DISCUSSION**

Paracetamol a widely used over-the-counter analgesic and antipyretic. Paracetamol toxicity is caused by excessive use or overdose of the analgesic drug paracetamol, mainly causing liver injury. Liver enzymes such as Alanine transaminase(ALT), Aspartate transaminase

(AST), Alkaline phosphatase (ALP) and Bilirubin serve as marker enzymes for liver function and integrity.

S.V.Suresh kumar *et al* (2012) [6], have observed a decrease in the hepatotoxic potential of paracetamol, which supports our present observation.Changes in the activities of serum marker enzymes are represented in Table 1.

A column means followed by different superscript are significant at 5% by DMRT.

Group 1: Control

Group 2: Induced(Paracetamol)

Group 3: Paracetamol+Standard(Silymarin)

Group 4: Paracetamol+Plant extract (*Foeniculum Vulgare*, Low dose 200mg/kg bw)

Group 5: Paracetamol+Plant extract (*Foeniculum Vulgare*, High dose 400mg/kg bw)

Enzyme units are expressed as: ALT, AST, ALP: IU/L

Bilirubin: mg/dl

There is a significant decrease in the activities of these enzymes in the tissues of rats treated with paracetamol indicating liver damage.

Simultaneous treatment with the plant extract of *Foeniculum vulgare* (High dose, 400 mg/kg bw, Group 5) showed near normal activity to control and hence reversing the effect of paracetamol toxicity in rats.

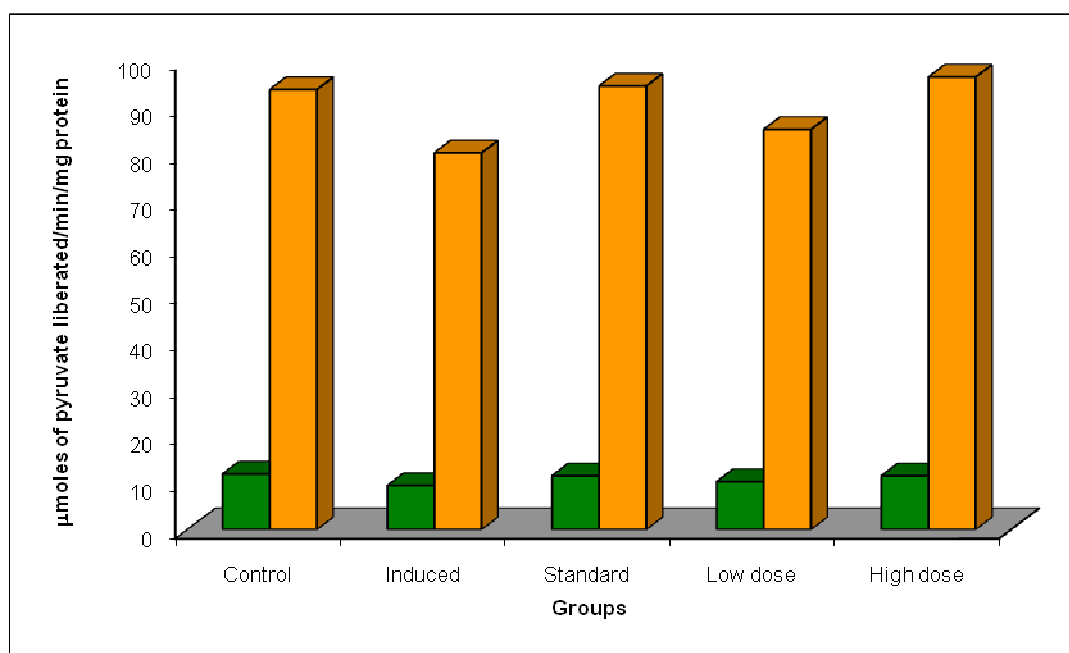


Fig. 4: activity of ast and alt in hepatic tissue of control and experimental animals

A column means followed by different superscript are significant at 5% by DMRT.

Treatment Groups are as in figure 1

Enzyme units are expressed as: ALT, AST: μmoles of pyruvate liberated/min/mg protein.

A marked increase in the activity of these enzymes was observed in the serum of rats treated with paracetamol, suggesting the hepatotoxic nature of the paracetamol. Hepatic necrosis caused by paracetamol is manifested as the release of enzymes into the serum, thereby increasing its activity.

Simultaneous treatment with the plant extract of *Foeniculum vulgare* (High dose, 400 mg/kg bw, Group 5) showed near normal activity to control and hence reversing the effect of paracetamol toxicity in rats.

Debosree Ghosh *et.al* (2013) [7] have observed a decrease in the hepatotoxic potential of paracetamol, which supports our present observation.

The activities of these enzymes are usually raised in acute hepatotoxicity or mild hepatocellular injury, but tend to decrease with prolonged intoxication due to damage to liver. There is a significant decrease in the activities of these enzymes in the tissues of rats treated with paracetamol indicating liver damage.

## CONCLUSION

Paracetamol a widely used over-the-counter analgesic and antipyretic. It is commonly used for the relief of headaches and other minor aches and pains and is a major ingredient in numerous cold and flu remedies.

Paracetamol toxicity is caused by excessive use or overdose of the analgesic drug paracetamol. Mainly causing liver injury,

paracetamol toxicity is one of the most common causes of poisoning worldwide. In the United States and the United Kingdom it is the most common cause of acute liver failure.

Plant and plant derived products have found to exhibit a wide variety of activity ranging from analgesic to antineoplastic. About 80% of the world population relies on the use of traditional medicines which is predominantly based on the plant materials. Either the whole plant or certain part of plant such as leaves, flowers, roots, fruits, etc are used for the treatment of various diseases. Plant possesses very efficient scavenging systems for reactive oxygen species that protect them from destructive oxidative reaction.

The study was carried out to determine the activities of serum marker enzymes, liver marker enzymes in the liver of control and experimental rats. The level of serum markers SGOT, SGPT, ALP and Bilirubin was estimated and found to be increased during paracetamol toxicity. The hepatic marker enzymes such as AST and ALT was estimated and found to be decreased in paracetamol induced hepatotoxicity. This observed hepatoprotection may be attributed to the presence of antioxidants defense systems which may bring the therapeutic approach to a variety of liver injuries.

## CONCLUSION

From the present study, it can be concluded that the extract of *Foeniculum vulgare* possess anti- hepatotoxic action against

paracetamol toxicity. Since it is the first time to carry out hepatoprotective activity in the medicinal plant *Foeniculum vulgare*, but the exact etiology, mode and the active components responsible for hepatoprotective action needs further studies.

#### ACKNOWLEDGEMENTS

We are thankful to our chairman Dr. Nalla.G.Palaniswami and our Secretary Dr. Thavamani.D.Palaniswami for providing research infrastructure. We are very much thankful to our principal DR. P.R.Muthusamy and my beloved guide DR. S.Mohandass for his constant support & encouragement throughout the study.

#### REFERENCES

1. Philip M, Benjamin L. Shneider; Sherman, 2008 Paediatric Gastrointestinal Disease. Connecticut: PMPH-USA. pp. 751. ISBN 1-55009-364-9
2. Sheen CL, Dillon JF, Bateman DN, Simpson KJ, Macdonald TM., 2000 "Paracetamol toxicity: epidemiology, prevention and costs to the health-care system". QJM: monthly journal of the Association of Physicians 95 (9): 609.
3. Cotran, Ramzi S.; Kumar, Vinay; Fausto, Nelson; Nelso Fausto; Robbins, Stanley L.; Abbas, Abul K. Robbins and Cotran., 2005 pathologic basis of disease (7th ed.). St. Louis, MO: Elsevier Saunders. p.878. ISBN 0-7216-0187-1.
4. Daly FF, Fountain JS, Murray L, Gaudins A, Buckley NA., 2008 "Guidelines for the management of paracetamol poisoning in Australia and New Zealand—explanation and elaboration. A consensus statement from clinical toxicologists consulting to the Australasian poisons information centres". *Med J Aust* 188 (5): 296–301. PMID18312195.
5. Chaterjee TK., 2000 Medicinal Plants with Hepatoprotective Properties, Herbal Options, Books & Allied (P) Ltd., Calcutta.;155.
6. S.V.Suresh kumar,G. Chandrika, K.Mahesh, PVS Meganath., 2012 Hepatoprotective activity of *Achyranthes aspera* linn against paracetamol induced toxicity International Journal of Pharmacy and Pharmaceutical Sciences Volume 4,Suppl 5.
7. Debosree Ghosh,Syed Benazir Firdaus *et.al*, 2013 Hepatoprotective activity of aqueous extract of *murraya koenigii* against lead induced hepatotoxicity in male wistar rats. International Journal of Pharmacy and Pharmaceutical Sciences, Volume 5, Suppl 1.